Concurrent Helminthosis and Plastic-induced Rumen Impaction in a Kano Brown Doe (*Capra hircus*): Clinical Management and Pathology Findings

A. C. Kogi*[1], D. O. Oshadu[1], G. P. Karaye[1], M. B. Biallah[1], C. U. Godwin[1], and D.M. Buba[2]

[1]Department of Veterinary Parasitology and Entomology, Faculty of Veterinary Medicine, University of Jos, Plateau State, Nigeria.
[2]Department of Veterinary Pathology, Faculty of Veterinary Medicine, University of Jos, Jos. Plateau State, Nigeria.
*Corresponding author email: kogiC@unijos.edu.ng; cecilkogi50@gmail.com

Received 10 May 2026, Accepted 1 July 2026, Published 8 July 2026

Direct Research Journal of Veterinary Medicine and Animal Science

Vol. 11(1), Pp. 59-65, July 2026,
Author(s) retain the copyright of this article
This article is published under the terms of the Creative Commons Attribution License 4.0.
https://journals.directresearchpublisher.org/index.php/drjvmas; https://www.ajol.info/index.php/drjvmas

Research Article
ISSN: 2734-2166

ABSTRACT

Background: *The role of livestock is pivotal in the livelihoods of rural and sub-urban communities. Small ruminants contribute substantially to food security, household income, and economic sustainability in sub-Saharan Africa. However, productivity is severely constrained by gastrointestinal helminthosis and rumen impaction. Nematodes are common causes of gastrointestinal infection especially Haemonchus contortus while rumen impaction is as a result of nutritional deficiencies and poor management practices.* ***Case Presentation:*** *A One-Year-old Kano Brown doe weighing 15.9 kg was presented to the Veterinary Teaching Hospital University of Jos, Jos, with the complaint of malaise, lethargy, rough hair coat, vocalization, pale mucous membranes, ataxia, and a history of anorexia.* ***Diagnosis:*** *On physical examination, ticks were observed on the body while abdominal ballottement revealed presence of a palpable hard mass in the caudal third of the left abdominal region. Clinical examination revealed that vital parameters: temperature, pulse and respiratory rate were all within normal range. Laboratory investigations revealed a PCV of 27%, TWBC 2800, while faecal floatation technique showed presence of strongyle type eggs +++ and coccidia oocysts ++.* ***Management/Treatment:*** *At presentation, the animal was stabilized with Dextrose saline and lactated Ringers' solution given intravenously. Dexamethasone was administered via the intramuscular route. The doe was scheduled for rumenotomy pending resuscitation.* ***Outcome:*** *Post-treatment monitoring showed that the doe was not improving, did not stabilize and eventually died.* ***Pathology Findings:*** *At post-mortem examination, a mass of plastic bag with trapped ingesta weighing 4.3 kg was recovered from the rumen. Further observation of the liver and kidneys revealed enlargement and congestion of the organs.* ***Conclusion:*** *Concurrent gastrointestinal helminthosis and plastic-induced rumen impaction is a major constraint to production performance of small ruminants in sub-Saharan Africa. This case report, though uncommon, highlights the severity and consequent economic impact of the condition on small ruminant holders. Helminthosis and foreign body rumen impaction have severe negative consequences on livestock production and reproduction, particularly in females. Efforts should be intensified to protect small ruminants especially goats and sheep from contaminated pastures and indiscriminate disposal of harmful and non-biodegradable materials in the environment, as well as discouraging the extensive system of management.*

Keywords*: Case Report, Doe, Environmental pollution, Gastrointestinal helminthosis, Goat, Kano Brown, Plastic foreign body, rumen impaction, Strongyle infection, small ruminants*

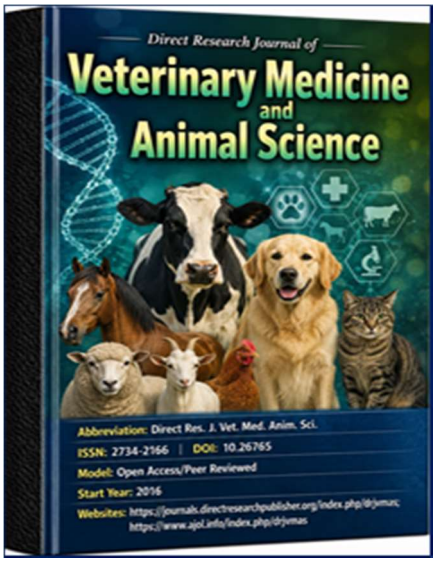

Citation: Kogi, A. C., Oshadu, D. O., Karaye, G. P., Biallah, M. B., Godwin, C. U., & Buba, D.M. (2026). Concurrent Helminthosis and Plastic-induced Rumen Impaction in a Kano Brown Doe (*Capra hircus*): Clinical Management and Pathology Findings. *Direct Research Journal of Veterinary Medicine and Animal Science. Vol. 11(1), Pp. 59-65.* https://dx.doi.org/10.4314/drjvmas.v11i1.1

INTRODUCTION

Livestock play a pivotal role in the livelihoods of communities in rural and sub-urban Africa. Considering the global population growth, livestock ought to scale up in order to meet the protein demands especially in sub-Saharan Africa, (Mwacalimba *et al*., 2025). More importantly, small ruminant production is of great significance in food security in small households in tropical Africa, Nigeria being inclusive, (Chukwu *et al*., 2025). Goats and sheep play a critical role in household income generation by converting low-quality roughage to high quality protein diets in the form of milk and meat. Thus, factors affecting the health and productivity of livestock are important constraints in the economic well-being of such communities (Kimeli et al., 2025; Grace *et al*; 2015; Chukwu *et al*., 2025). Gastrointestinal (GIT) helminthosis is a major constraint in sheep and goat production in Nigeria, with high prevalence rates due to a variety of nematodes, trematodes, and cestodes, particularly *Haemonchus contortus, Ostertagia*, *Trichostrongylus commonly referred to as the* ("HOT" complex). Other nematodes and trematodes include *Oesophagostomum*, *Strongyloides*, and *Fasciola* species respectively. Sustainable control requires integrated parasite management, mitigation of anthelminthic resistance (AR), improved environmental sanitation, and context-specific research to enhance animal health and production. Although all grazing small ruminants may be infected with these parasites, low worm burdens usually have little impact on animal health, however, with increased worm burden, the effects are seen in the form of reduced weight gain due to decreased appetite. With heavier worm burdens, the disease is clinically characterized by progressive anaemia, weight loss, diarrhoea, and sub-mandibular oedema (bottle jaw).

In goats, helminthosis continues to be one of the major constraints for small ruminant production in many areas of the world, including Nigeria (Jatau et al., 2011). Studies in various parts of the world have shown that the high incidence of these infections is season-related (Yadev and Khajuria., 2006). Although they occur in all age groups, they are more prevalent in kids when exposed to contaminated feed and water. In most studies, *Haemonchus contortus, Strongyloides papillosus, Trichostrongylus colubriformis, Fasciola* species, and *Moniezia benedeni* have been reported as the most common helminths in goats; hence, helminthosis has long been recognised as a major problem in livestock rearing (Aliyu *et al*., 2020).

Other parasites which equally constitute serious constraints to smallholder farmers are lungworm infestation, fascioliasis and, less frequently, coenurosis. Other important diseases of small ruminants include *peste des petits ruminants*; sheep and goat pox; contagious ecthyma (orf); contagious caprine pneumonia; anthrax; pasteurellosis; and ectoparasites (Phetla *et al*., 2024).

The driving factors of helminths parasitism in ruminants are various and often interactive, most cases result from switching host vulnerability, a high number of infective larval stages (L3) on forage, influx of susceptible animal populations into infected domains, anthelmintic resistance, poor management or abuse of helminthic medications.

Hirusa *et al* (2021) reported a prevalence of 80 % and 87 % in goats and sheep respectively due to infections with *Trichostrongylus* and *Haemonchus* species with high production losses as a result of mortality and reduced weight gain in affected animals. GIT parasitism caused by nematodes constitutes a major challenge in productivity and affects reproductive performance of small ruminants in sub-Saharan Africa (sSA). All of these economically important parasites have direct life cycle with the third larval instar (L3) being the infective stage; hence, they do not require an intermediate host. Mature parasites breed inside the host up to egg laying stages. The eggs are voided in the faeces and passed into the environment where they hatch into first-stage larvae (L1), which moult into L2 and subsequently into the L3 infective stage, which emerge out of the faeces, attaches to the forage and waits for a host under conducive environmental conditions such as temperature and humidity. The ingested L3 continues to develop within the host, changing to L4 and L5 and eventually developing into the adult worm. The infective stage of certain unique parasites enters the host mainly through penetration of the skin. Examples of such include *Bunostomum* and *Strongyloides* species. These eventually get to the lungs through the heart via venous circulation, where they are coughed up into the oral cavity and swallowed back into the GIT (Fasil, 2016).

Clinical Signs

One typical clinical sign of nematodiasis is anaemia due to direct haematophagous (blood-feeding) activity of the parasite, diarrhoea (gastroenteritis), weight loss, weakness, caused by reduced feed intake due to depression and indigestion.

Pathogenesis

Pathogenesis of *H. contortus* in sheep and goat manifests in three forms, and all of these are related to the blood-sucking activities of the L4, L5 larval stages, and the adult worm. They include the following forms:
Hyperacute form, in which the animal might be dead without clinical symptoms as a result of blood loss anaemia; acute form, whose symptoms include pale mucous membrane and conjunctiva, weight loss and hyperproteinaemia; chronic-lethargy, muscular weakness, pale mucous membrane and conjunctiva and oedema.

Recent Advances in the Control of Gastrointestinal Helminthosis in Small Ruminants

Recent advances in the control of gastrointestinal helminthosis in small ruminants have shifted, and the general use of therapeutics in the treatment and control of diseases is rapidly evolving from routine mass deworming

and treatment to integrated parasite management (IPM) and targeted selective treatment (TST), (Mwacalimba et al., 2025). This is also because of the observation that eighty percent (80 %) of parasite load in a herd or flock are usually present in only about 20 % of animals. Also, because of the growing and widespread anthelminthic resistance (AR), targeted selective treatment and deworming is being advocated rather than blanket mass treatment, thereby, ensuring that only animals showing clinical signs using tools such as FAMACHA to assess anaemia are treated. Pasture rotation (rotational grazing and resting pasture), by rotating young animals through pasture before older ones minimises exposure of young animals whose immunity is not fully developed to a large infective L3 burden. Rotational grazing and resting pastures for about 30 days or more is also used to allow larvae to die off is another proper pasture management strategy.

Genetic Selection

This involves using high genetic profile breeding stock to enhance resistance against parasites. It is the ability to limit worm burden or resilience to maintain productivity despite infection through the selection of breeding stocks of high pedigree and the provision of adequate nutrition and minerals to support the animal's immune response to challenges of parasite infection (Anna *et al*., 2023).

RUMEN IMPACTION

Productivity of sheep and goats in developing countries is generally low mainly due to under feeding, poor management systems and several disease-causing agents. Environmental pollution which is a non-infectious condition is a growing concern for grazing animals because of absence of recycling industries, improper disposal of non-biodegradable and indigestible wastes, especially plastic bags, lack of implementation of strict cleaning culture and less awareness about the harmful effects of these wastes, (Yusuf *et al*., 2018). Plastic bags are non- biodegradable and indigestible, hence their lodgement in the rumen of grazing animals leads to diverse effects on the health of animals. The exposure of animals to these wastes is because local authorities often do not provide the necessary waste management amenities nor fulfil obligations that can enable the management of these wastes, (Kumari and Raghubanshi, 2023). Ingestion of foreign bodies can be traced to nutritional deficiencies, poor feeding and management practices where animals especially female sheep and goats develop pica, (Sandeepa *et al*., 2019). Rumen impaction is uncommon in small ruminants especially goats, hence the novelty in this report, however, where it does occur, females are the most susceptible as reported by Lawal et al, (2026) in a retrospective study conducted in Bauchi state, Nigeria. The condition is caused by feeding on indigestible wastes and can also be traced to pica, excessive confinement, poor nutrition and mineral imbalances, (Farooq *et al*; 2024). The entry and migration of foreign bodies in the rumen leads to many complications depending on the nature of the foreign body. Several reports from cattle and sheep indicate that impaction of the rumen resulting from the accumulation of foreign bodies like plastic bags cause interference with the flow of ingesta leading to constipation, distension of the rumen, absence or reduced rumen motility and absence of defaecation. It also hampers the absorption of free volatile fatty acids and consequently reduces the rate of animal fattening. In sheep and goats, the forestomach is highly affected by ingested foreign bodies; this is of great economic importance and causes severe production losses through morbidity and sometimes mortality. The phenomenon of ingestion and lodgement of foreign bodies is primarily a serious challenge in developing countries because of unsatisfactory standard of management (Fasil, 2016); (Kumari and Raghubanshi, 2023). However, there is paucity of information on reports describing concurrent helminthosis and rumen impaction, though reports on the individual conditions may be common.

CASE REPORT

A One-Year-old Kano Brown doe weighing 15.9 kg was presented to the large animal clinic floor of the Veterinary Teaching Hospital, University of Jos, Jos, Plateau State, Nigeria, with a complaint of weakness, rough hair coat, vocalisation, slight pale mucous membranes and ataxia. The animal was earlier observed to be sluggish and not feeding normally for a period of one week before presentation. The animal was reared among a flock of twenty-five animals comprising sheep and goats. Upon physical examination, ticks were seen on the body of the doe, the abdomen was observed to be distended, and a hard mass was felt in the rumen on palpation; hence, the patient was immediately booked for rumenotomy. Clinical examination revealed that vital parameters — temperature, pulse and respiratory rates were within normal range as shown in (Table 1). However, the doe was too weak to undergo the said surgical procedure immediately.

Table 1: Observed and referenced vital parameters of the Kano Brown Doe Diagnosed with helminthosis and ruminal impaction

Parameter	Observed Value	Reference Range
PCV	27%	22-38.6%
WBC	2800 cells/µL	4000-13,000 cells/µL
Temperature	33.0°C	38.6-40.2°C
Pulse Rate	80bpm	70-90bpm
Resp. Rate	26	20-30

While waiting for the patient to become stabilized, it became recumbent. Post treatment monitoring showed the doe was not improving. While managing the patient to become fit for the procedure, further investigations were

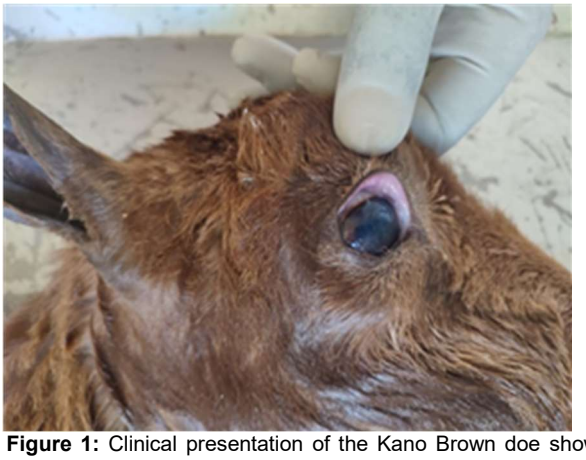

Figure 1: Clinical presentation of the Kano Brown doe showing mild paleness of conjunctiva

Figure 2: Clinical Presentation of the Kano Brown doe showing mild paleness of jingiva

Figure 3: Clinical Presentation of the Kano Brown doe showing severe weakness and recumbency

carried out by sending blood and faecal samples to the diagnostic laboratories of the Haematology and Parasitology units in the Departments of Pathology and Parasitology, respectively. Laboratory investigations revealed a PCV of 27%, TWBC 2800, while faecal floatation technique showed presence of strongyle type eggs +++ and coccidia oocysts ++. The parasitological investigation showed the presence of *Strongyle* type eggs +++ and coccidia oocysts ++ at X4 and X10 respectively. The doe died five days after presentation before the prescribed rumenotomy was carried out, hence, post-mortem examination was conducted. Clinical presentation of the Kano Brown doe showing mild paleness of ocular and gingiva mucous membranes (Figures 1&2). Figure 3 shows the clinical presentation of the Kano Brown doe showing severe weakness and recumbency.

Post Mortem Findings

The carcase was immediately sent to the post mortem (PM) unit of the Department of Pathology of the Veterinary Teaching Hospital, University of Jos to conduct post-mortem examination. Post-mortem findings showed that the carcase was in a poor body condition**.** The liver and kidney were mildly enlarged and firm to touch (Figure 4). The abdomen of the carcase was opened, and the rumen and reticulum were examined and carefully removed from the abdominal cavity and explored for the presence of foreign non-dietary material by visualisation and palpation. A hard mass was palpated, upon incision, a black polythene bag with trapped ingesta was found which 4.3 kg weighed. (Figures 5-7).

;;

Figure 4: Pathology presentation of the gross appearance of the liver of the Kano Brown doe showing severe hyperaemia, hepatomegaly and distended Gallbladder.

Figure 5: (A&B) Pathology presentation of the gross appearance of enlarged pair of Kidneys of the Kano Brown doe showing severe hyperaemia and degenerated trabeculae.

Figure 6: Post mortem presentation of the gross appearance of the rumen of the Kano Brown doe showing enlargement due to Impaction foreign body *in situ*.

Figure 7: Post mortem presentation of the gross appearance of the rumen of the Kano Brown doe showing the black polythene bag and Ingesta after incision

DISCUSSION

Gastrointestinal tract (GIT) helminthosis and rumen impaction are a widespread challenge and have been reported especially in sub-Saharan Africa, (Chukwu *et al.*,2025); Jesse *et al.*, 2019); Kumari and Raghubanshi, (2023); Lawal *et al.*, (2026); (Hurisa *et al.,* 2021). In chronic and severe helminthosis, caused by *H. contortus* medical management employs blood transfusion as reported by Jesse *et al.,* (2019), where a PCV as low as 9% was recorded in contrast with this present case report where the PCV was 27% which is within a score range 2 using FAMACHA scoring which is considered to be within normal range for the species involved. In this case report, being concurrent helminthosis and rumen impaction, the life-threatening condition was the rumen impaction, which was most incriminated as the primary cause of the death of the doe. However, there is paucity of information on concurrent helminthosis and rumen impaction. Rumen impaction is rampant especially in communities where local authorities fail to fulfil waste management obligations leading to widespread mismanagement of plastic waste, Kumari and Raghubanshi, (2023).

Helminthosis and rumen impaction are co-factors of environmental exposure, age, sex and management practices, as well as the susceptibility of the species involved (Yusuf *et al*., 2018). The novelty in this uncommon concurrent case report is an enlightenment to the small ruminant farmer, especially goats and sheep, demonstrating that free-range grazing or semi-intensive management systems should not be encouraged. Exposure to both conditions can also be attributed to lack of selection of high-profile stocks and inadequate provision of nutritional components in the ration because of which animals easily develop pica, unable to develop resistance and immunity against these environmental challenges. (Oyenekan et al., 2024). Poor cleaning culture of environment, indiscriminate disposal of indigestible and non-biodegradable plastics and polythene bags and sharp objects constitute pre-exposure to rumen impaction, (Kumari and Raghubanshi, 2023). While helminthosis is seasonal, with a spike during the wet season where there is increased larval burden, rumen impaction is equally age and sex related, though studies have also related it to seasons of feed scarcity, but more of poor management practices, Lawal *et al*., (2026). These factors combined create a high tendency for helminthosis and rumen impaction to co-exist in small ruminants, especially in goats that are naturally aggressive and hardy browsers for food.

Since sheep and goats constitute an important means of livelihood among farmers and herders in sSA, the economic impact of helminthiasis alongside other aggravating conditions such as rumen impaction, as seen in this case report, can be far-reaching. More so, the low productivity can be attributed to these disease conditions, poor feed quality, low-profile breeds and inadequate management practices. *Haemonchus and Trichostrongylus* constitute a significantly high percentage of parasite infections in sheep and goats leading to production losses such as reduced weight gain, decreased milk production and fertility alongside direct morbidity and mortality in affected animals as reported by Hirusa *et al;* (2021) who reported high production losses where disease prevalence as high as 80 % and 87 % in goats and sheep respectively was reported. Proper management strategies have shifted from routine mass deworming and treatment to integrated parasite management (IPM) and targeted selective treatment (TST), because of the observation that eighty percent (80 %) of parasite load in a herd or flock are usually present in only about 20 % of animals and at the same time, the growing and widespread anthelminthic resistance (AR) by livestock, hence targeted selective treatment and deworming is being advocated rather than blanket mass treatment thereby treating only animals showing clinical signs using FAMACHA that can assess anaemia, and pasture rotation (rotational grazing and resting pasture). Rotating young animals through pasture before older ones to minimise exposure of young animals whose immunity is not fully developed to a large infective L_3 burden. Rotational grazing and resting pastures for about 30 days or more to allow larvae to die off.

Recently exploration of alternative treatments using bioactive plant compounds like *Azadirachta indica* (neem plant) and selection of genetically resistant breeds have been documented by Anna *et al*. (2023), Maestrini *et al.* (2021) and Challaton *et al.* (2024).

Powders and leaf extracts of plants have been shown to have over 50% significant *in- vivo* reduction in egg excretion, larval establishment, viability and fertility of gastrointestinal strongyles in small ruminants. The extracts of some plants have also revealed *in-vitro* inhibition of over 50% of egg hatching, larval migration and motility of gastrointestinal strongyles as revealed in their reviewed studies.

Lack of exclusive and early clear clinical signs of rumen impaction often leads to delayed treatment, and consequent delayed lifesaving laparotomy or rumenotomy. It is sometimes only diagnosed at post-mortem, which was the case with the animal in this report, and agrees with the findings of Akinrinmade and Akinrinde (2013); Priyanka and Dey (2018). However, timely diagnosis and immediate surgical intervention can considerably curtail the incidence as well as prevalence of mortality not only in small ruminant impaction, but including other livestock, (Oyenekan *et al*., 2024). Presence of a polythene bag in the rumen could have also elicited a higher and unprecedented degree of inflammation and hypersensitivity reaction that is greater than that which the helminth parasites could do. It could also have impeded proper absorption of dexamethasone, the anti-inflammatory agent that was administered which could have managed severe tissue damage and the hypersensitivity.

CONCLUSION

In conclusion, this case highlights that concurrent gastrointestinal helminthosis and plastic-induced rumen impaction on goat's health is severe, fatal and a debilitating condition, hence early veterinary clinical intervention is critical. It underscores the clinical significance and the need to employ Integrated parasite management (IPM), targeted selective treatment (TST), and use of FAffa MAlan CHArt (FAMACHA), a tool that assesses paleness of mucous membranes as an index of anaemia especially in *H. contortus* infection (barber's pole worm) to curb AR. Rotating young animals through pasture before older ones to minimize exposure of young animals, grazing and resting pastures for about 30 days or more to allow larvae to die off, exploring alternative treatments using bioactive plant compounds like the neem plant and selection of genetically resistant breeds as documented by Anna *et al*., (2023); Maestrini *et al.;* (2021) and Challaton *et al;* (2024) should be adopted. Efforts should be intensified to protect small ruminants especially goats and sheep from contaminated pastures and indiscriminate disposal of harmful and non-biodegradable materials in the environment, as well as discouraging the extensive system of grazing.

RECOMMENDATIONS

Awareness on the danger of rumen impaction with non-biodegradable materials, polythene and plastic, sharp objects, especially open grazing around new construction sites should be created among small ruminant holders. Proper disposal of plastics and metal wastes in the environment should be practised. Standard nutritional and management systems should be adopted (Oyenekan *et al*., 2024). Salt licks should be provided *ad libitum* to reduce the incidence of consumption of non-digestible materials as a result of animals developing pica. Sheep and goats should be provided with adequate feed of good quality and quantity in all seasons to avoid pica, especially in females both peripartum and postpartum who require high nutrition programme, (Lawal *et al*., 2026). Recent advances in monitoring, prevention and control of small ruminant helminthosis should be adopted, location specific epidemiology data should be created, integrated parasite management (IPM), targeted selective treatment (TST), and the use of FAMACHA for assessment of anaemia to reduce indiscriminate use of anthelminthics to curb anthelminthic resistance (AR), should be encouraged (Chukwu et al., 2025; Adduci, 2022).

REFERENCES

Adduci, I., Sajovitz, F., Hinney, B., Lichtmannsperger, K., Joachim, A., Wittek, T., & Yan, S. (2022). Haemonchosis in sheep and goats, control strategies and development of vaccines against Haemonchus contortus. *Animals*, *12*(18), 2339.

Challaton K.P., Akouedegni C.G., Alowanou G.G., Boko K.C., Toklo P.M., Hounzangbé-Adoté M.S, (2024). Gastrointestinal anthelmintic plants used on small ruminants in Benin: Traditional use and scientific results: Review. Veterinary Parasitological Registered Study Reports. 50:101015. doi: 10.1016/j.vprsr.2024.101015.38644039.

Farooq A, Murtaza S, Ahmad E, Lashari M, Javid M, Saleem M, et al, (2024). Surgical treatment of severe ruminal impaction and dystocia in beetal goat. *Bioogical and Clinical Science Research Journal.* 2024(1):771. https://bcsrj.com/ojs/index.php/bcsrj/article/view/771.

Fasil, N. (2016). Assessment of sheep and goat foreign bodies in rumen and reticulum in the Jigjiga municipal Abattoir. *Journal of Advance. Dairy Research*, *4*(3), 157. doi:10.4172/2329-888X.1000157.

Grace, D., Bett, B. K., Lindahl, J. F. and Robinson, T. P. (2015). Climate and livestock disease: assessing the vulnerability of agricultural systems to livestock pests under climate change scenarios.

Hurisa, G., Yimer, L., and Amante, M. (2021). Species composition and burden of small intestinal parasitic helminth in goats and sheep slaughtered at Bishoftu Elfora export abattoir. (Ethiopia). *Veterinary Medicine: Research and Reports*, Med. AUCKL. 12:235-239.

Jatau, I. D., Abdulganiyu, A., Lawal, A. I., Okubanjo, O. O., and Yusuf, K. (2011). Gastrointestinal and haemo-parasitism of sheep and goats at slaughter in Kano, northern-Nigeria. *Sokoto Journal of Veterinary Sciences*, *9*(1), 7-11.

Jesse, F. F. A., Chung, E. L. T., Abba, Y., Lila, M. A. M., Aishah, S. N., Affandi, S., and Hambali, I. U. (2019). A veterinary clinical case of severe chronic haemonchus contortus infection in a goat: the clinical management of the case and pathology findings. *Advance Animal Vetetrinary Science*, *7*(6), 503-507.

Jatau, I. D., Abdulganiyu, A., Lawal, A. I., Okubanjo, O. O., & Yusuf, K. (2011). Gastrointestinal and haemo parasitism of sheep and goats at slaughter in Kano, northern-Nigeria. *Sokoto Journal of Veterinary Sciences*, *9*(1), 7-11.

Khajuria, J. K., Katoch, R., Yadav, A., Godara, R., Gupta, S. K., & Singh, A. (2013). Seasonal prevalence of gastrointestinal helminths in sheep and goats of middle agro-climatic zone of Jammu province. *Journal of*

Parasitic Diseases, *37*(1), 21-25.

Kimeli, P., Mwacalimba, K., Tiernan, R., Mijten, E., Miroshnychenko, T., and Poulsen Nautrup, B. (2025). Important diseases of small ruminants in sub-Saharan Africa: a review with a focus on current strategies for treatment and control in smallholder systems. *Animals*, *15*(5), 706.

Kumari, T., and Raghubanshi, A, (2023). Waste management practices in the developing nations: challenges and opportunities

Editor(s): Pardeep Singh, Pramit Verma, Rishikesh Singh, Arif Ahamad, André C.S. Batalhão, Pages 773-797, ISBN 9780323904636, https://doi.org/10.1016/B978-0-323-90463-6.00017-8.

Kumar, S., Sieverding, H., Lai, L., Thandiwe, N., Wienhold, B., Redfearn, D., & Jin, V. (2019). Facilitating crop–livestock reintegration in the Northern Great Plains. *Agronomy Journal*, *111*(5), 2141-2156.

Lawan, S., Shuaibu, B., Abubakar, M., Haliru, M., Ibrahim, U., Zakka, T., & Abdullahi, U, (2026). Prevalence of Rumen Impaction in Small Ruminant (Sheep and Goat) in Bauchi Metropolis. *Nigerian Journal of Animal Science*, *27*(2), 193–197. https://njas.org.ng/index.php/php/article/view/1429.

Mwacalimba, K., Kimeli, P., Tiernan, R., Mijten, E., Miroshnychenko, T., & Poulsen Nautrup, B. (2025). Diseases of economic importance in feedlot cattle in Sub-Saharan Africa: A review with a focus on existing and potential options for control. *Animals*, *15*(1), 97.

Maurizio, A., Perrucci, S., Tamponi, C., Scala, A., Cassini, R., Rinaldi, L., & Bosco, A. (2023). Control of gastrointestinal helminths in small ruminants to prevent anthelmintic resistance: the Italian experience. *Parasitology*. 150(12):1105–1118. https://doi.org/10.1017/S0031182023000343

Maestrini M, Molento MB, Forzan M and Perrucci S (2021). In vitro anthelmintic activity of an aqueous extract of Glycyrrhiza glabra and of glycyrrhetinic acid against gastrointestinal nematodes of small ruminants. Parasite. 28:64. doi: 10.1051/parasite/2021060. Epub 2021 Sep 1. PMID: 34468311; PMCID: PMC10649775.

Oyenekan, I. O., Kilani, M. A., Makinde, O. A., & Koleoso, S. A. (2024). Surgical management of rumen impaction in a four-year-old Uda ewe. *Savannah Veterinary Journal*, *7*(1).

Phetla, V., Chaisi, M., and Malatji, M. P. (2024). Epidemiology and diversity of gastrointestinal tract helminths of wild ruminants in sub-Saharan Africa: a review. *Journal of Helminthology*, *98*, e45. doi:10.1017/S0022149X24000361.

Priyanka, M., and Dey, S. (2018). Ruminal impaction due to plastic materials-An increasing threat to ruminants and its impact on human health in developing countries. *Veterinary world*, *11*(9), 1307.

Yusuf, A., Aruwayo, A., and Maigandi, S. (2018). Survey of Rumen Impaction in Goat from Katsina Metropolis, Katsina State, Nigeria. *Journal of Applied Sciences and Environmental Management*, *22*(5), 713–718. https://doi.org/10.4314/jasem.v22i5.16.