

Comparative Pathophysiological Changes in Red Sokoto Bucks Following one and two Clamp Burdizzo Castration

Okunowo, O.O.^{1,2,3}, Adeusi, A.A.^{1,2,3}, Oloye, A.A.¹, Hassan, J.O.¹, Omosanya, O.K.¹, Oni, O.O.¹, Bassahwa, A.P.¹, Ajayi, O.L.¹, and Sonibare, A.O.¹

¹Department of Veterinary Surgery and Reproduction, Federal University of Agriculture, Abeokuta.

²Department of Veterinary Services, Ministry of Agriculture and Food Security, Ogun State, Nigeria

³Postgraduate College of Veterinary Surgeons of Nigeria, Abuja, Nigeria.

Corresponding Author: drniyiadeusi@gmail.com; 07068814156

Direct Research Journal of Veterinary Medicine and Animal Science



Vol. 11(1), Pp. 29-39, May 2026

Author(s) retains the copyright of this article

This article is published under the terms of the

Creative Commons Attribution License 4.0.

<https://journals.directresearchpublisher.org/index.php/drjvmas>; <https://www.ajol.info/index.php/drjvmas>

Research Article

ISSN: 4372-2601

Received 10 March 2025, Accepted 3 April 2026, Published 7 May 2026

ABSTRACT

The study evaluated the comparative effects of one and two clamp Burdizzo castration techniques on body weight, scrotal circumference, semen characteristics, serum testosterone, and testicular histology in Red Sokoto bucks. Eleven bucks were randomly assigned into three groups: one clamp (n=4), clamp (n=4), and control (n=3). Parameters were assessed weekly for four weeks. Both castration methods caused marked reductions in testosterone levels, semen quality, and sperm production, with complete azoospermia achieved earlier in the two-clamp group (week 3) compared to the one clamp group (week 4).

Histopathology revealed severe degeneration of seminiferous tubules and coagulative necrosis, more pronounced in the two-clamp group.

These findings demonstrate that while both techniques are effective for bloodless castration, the two-clamp method induces faster and more severe testicular degeneration. This has practical implications for reproductive control and herd management in goat production systems.

Keywords: *Burdizzo, Castration, Red Sokoto bucks, Spermogram, Testicular histology, Azoospermia*



Direct
RESEARCH JOURNALS

Citation: Okunowo, O.O., Adeusi, A.A., Oloye, A.A., Hassan, J.O., Omosanya, O.K., Oni, O.O., Bassahwa, A.P., Ajayi, O.L., Sonibare, A.O.(2026).Comparative Pathophysiological Changes in Red Sokoto Bucks Following one and two Clamp Burdizzo Castration.*Direct Research Journal of Veterinary Medicine and Animal Science*. Vol. 11(1), Pp. 29-39.
[.https://doi.org/10.26765/ DRJVMAS29653506](https://doi.org/10.26765/DRJVMAS29653506)

INTRODUCTION

Small ruminant production plays a critical role in food security, income generation, and rural livelihoods in many developing countries, including Nigeria. Among indigenous breeds, the Red Sokoto goat is particularly valued for its adaptability, high-quality skin, and meat production potential. Efficient reproductive management is essential for optimizing productivity in these systems, and castration remains one of the most widely used management practices in male livestock.

Castration is defined as the removal or functional inactivation of the testes, resulting in suppression of spermatogenesis and testosterone production. The procedure is commonly performed to control breeding, reduce aggressive behavior, and improve carcass quality. Various techniques are available, including surgical castration and non-surgical methods such as elastration and Burdizzo castration. The Burdizzo method, which involves crushing the spermatic cord without incision, is particularly favored in field conditions due to its simplicity and reduced risk of hemorrhage and infection.

Despite these disadvantages, increasing attention has been directed toward the welfare implications of castration procedures. Recent studies have demonstrated that even bloodless techniques such as Burdizzo castration can induce significant pain, stress responses, and behavioural changes in livestock (Robertson *et al.*, 1994). Observable indicators such as reduced feed intake, altered posture, and decreased activity have been widely reported as markers of pain in small ruminants following routine husbandry procedures (Kongara *et al.*, 2023; Vinicius *et al.*, 2022). Consequently, modern livestock management practices emphasize the incorporation of analgesic strategies to mitigate pain and improve animal welfare outcomes.

The physiological effects of castration are primarily mediated through disruption of testicular blood supply, leading to ischemia, hypoxia, and progressive degeneration of testicular tissue. The testes consist of seminiferous tubules responsible for spermatogenesis, supported by Sertoli cells, while Leydig cells located in the interstitial tissue are responsible for testosterone production. Compromise of these structures results in impaired sperm production, reduced sperm quality, and decreased circulating testosterone levels. Recent studies have further demonstrated that vascular occlusion leads to alterations in testicular hemodynamics and triggers molecular pathways associated with cellular degeneration and apoptosis (Akhigbe *et al.*, 2024).

In addition to structural damage, castration has profound effects on semen characteristics, including reductions in semen volume, motility, concentration and increased morphological abnormalities of spermatozoa. These changes reflect the progressive disruption of spermatogenesis and epididymal function following testicular degeneration. Recent research has shown that oxidative stress and hypoxia resulting from vascular

compromise contribute significantly to sperm defects and reduced fertility potential in male animals (Maxim *et al.*, 2021). Although the Burdizzo method is widely used, variations in technique particularly the number of clamps applied to the spermatic cord may influence the extent and rate of testicular degeneration. The two clamp method is hypothesized to cause more complete vascular occlusion compared to the one clamp method, potentially leading to faster onset of reproductive failure. However, there is limited recent comparative data evaluating the physiological, reproductive and histopathological outcomes of these techniques, especially in indigenous goat breeds such as the Red Sokoto. Therefore, this study was designed to comparatively evaluate the effects of one and two clamp Burdizzo castration technique on body weight, scrotal circumference, semen characteristics, semen testosterone levels, and testicular histopathology in Red Sokoto bucks. The findings of this study will contribute to improving castration practices by balancing effectiveness with animal welfare considerations in small ruminant production systems.

MATERIALS AND METHODS

The research was carried out in the department of Veterinary Surgery and Theriogenology, College of Veterinary Medicine (COLVET), Federal University of Agriculture, Abeokuta (FUNAAB), Ogun State, South West, Nigeria. The protocol for this study was in accordance with COLVET ethical guidelines on the use of experimental animals for experiments. (As at the time the research was conducted in 2016, the college did not have ethical committee and instead relied on departmental boards to approve research before it commenced.)

Experimental Animals

A total of 11 apparently healthy, sexually matured Red Sokoto Bucks aged 1-2 years old, obtained from the open Kuto market were used for this study. They were acclimatized, screened for endo- and ectoparasites, and administered prophylaxis antibiotics for two weeks before the commencement of the work. They were fed with concentrates and dried grass once daily and given water (*ad libitum*). The scrotum and testes were palpated to ascertain the suitability of each goat for the study. Bucks were allocated randomly into three groups. Group 1, control group (n=3); group 2, one clamp burdizzo group (n=4), and group 3, two clamps burdizzo group (n=4). The sample size was limited due to logistical and financial constraints; however, it was sufficient to demonstrate observable differences between treatment groups.

Burdizzo Application

The goats were properly restrained, then the hind limbs

were raised thereby exposing and isolating the scrotum for burdizzo castrator application. The burdizzo was applied once on each spermatic cord close to the testes, above the epididymal head in one clamp burdizzo group, while it was applied over two areas of each spermatic cord, (one close to the testis above the epididymal head and the other in the mid region of the spermatic cord) in two clamps burdizzo group. For both groups, the clamping was sustained for 30 seconds before burdizzo was released. The control group was left intact. Animals were monitored closely for pain and distress following the procedure. Although, no analgesics were administered, clinical signs such as recumbency and anorexia were recorded and interpreted as indicators of procedural discomfort. Future studies should incorporate analgesic protocols to improve animal welfare.

Weight

Prior to burdizzo application, the weight of the animals were taken with a weighing scale in kg. This was repeated weekly until azoospermia was observed.

Scrotal Circumference

Prior to the application of the burdizzo castrator, the scrotal circumference of the bucks were measured with a tape rule in centimeters. This was repeated once weekly in the bucks to check for testicular changes in size.

Semen Collection and Evaluation

Semen samples were collected from all bucks using an electro-ejaculator at the beginning of the study before burdizzo application to evaluate the semen volume, colour, concentration, motility, livability and morphology of the sperm cells. This was repeated every week until azoospermia was observed. The prepuce of the goats were neatly clipped and swabbed with methylated spirit before semen collection. The probe of the electro-ejaculator was lubricated with petroleum jelly and inserted into the rectum of the goats. The animals were stimulated by electrical current released from the rheostat, connected to the probe. Semen evaluation was conducted using standard procedures as described in reproductive physiology literature (Senger, 2020) for ejaculate volume, semen colour, progressive motility, spermatozoa concentration, spermatozoa percentage livability and spermatozoa morphological abnormalities.

Semen Volume

Semen samples were collected into calibrated collection tubes to determine the semen volume in mls.

Semen Colour

Semen colour was determined visually and were

classified into creamy, milky and watery according to Kanchan & Matharoo, 2026.

Sperm Motility

Immediately after semen collection, a drop of semen was placed on a pre-warmed glass slide with a drop of 2.9% Sodium citrate buffer. A cover slip was then placed on the slide. The slide was viewed under the microscope at x 40 magnification to check for progressive motility. This was scored according to Chenoweth, 2002. 70% Very Good (VG), 50 - 69% Good (G), 30 - 49% Fair (F), 30% Poor (P).

Spermatozoa Concentration

Neubauerhaemocytometer was used to determine sperm concentration. A drop of semen was placed in a sample bottle, then nine drops of formol saline was added to make a 1:10 dilution to de-activate the sperm cells. A warm glass slide was placed on the haemocytometer, it was then charged with the semen and formol saline mixture. The Neubauerhaemocytometer was mounted on a light microscope and focused at x40 magnification. Sperm heads in five large squares guided by three grid lines were counted according to Chenoweth 2016.

Spermatozoa livability

A drop of semen was placed at the tip of a pre-warmed glass slide, a drop of Eosin/Nigrosin stain was placed beside it and then they were mixed together with a glass slide. The glass slide used to mix was then used to make a smear on another glass slide and then the smear was left to air dry. It was viewed under the microscope at x100 magnification using oil immersion. The intact cell membranes that resisted the stain were counted. (Chenoweth 2016).

Semen pH

Semen pH was determined by inserting a pH meter into the collected semen and read.

Spermatozoa Morphological Abnormalities

A drop of semen was placed at the tip of a prewarmed glass slide, a drop of Eosin/Nigrosin stain was placed beside it and then they were mixed together with a glass slide. The glass slide used to mix was then used to make a smear on another glass slide and then the smear was left to air dry. It was viewed under the microscope at x100 magnification using oil immersion. One hundred cells were counted in each slide and classified into normal and

abnormal (Chenoweth 2016).

Serum Testosterone Evaluation

Enzyme Linked Immuno- Sorbent Assay (ELISA) was used for serum testosterone assay. Prior to the burdizzo castration, blood samples were collected by jugular venipuncture from the three groups and spinned with a bucket centrifuge at 3000 rpm for 15 minutes to separate the serum into eppendorf tubes. This was also repeated once weekly until azoospermia was observed. Serum samples were frozen in preparation for ELISA.

The materials provided with the ELISA test kit (Bio-Inteco, Catalog Number 10007) were Goat Anti- Rabbit IgG- coated microtiter wells, 96 wells, Testosterone Reference Standards; 0, 0.1, 0.5, 2.0, 6.0 and 18.0 ng/ml. Liquids, 0.5mL each, ready to use, Rabbit Anti-Testosterone Reagent 7 mL, Testosterone- HRP Conjugate Reagent, 12mL, TMB Substrate, 12 mL, Stop Solution, 12 mL, Wash Buffer Concentrate (50X), 15ML, Control 1 and 2.

All reagents were brought to room temperature before use. 10 mL of wash buffer was diluted with 490 mls of distilled water. The assay was done according to the manufacturer's instruction.

The microwells of the testosterone Elisa plate were secured in the holder. 10µl of standards, specimens and controls were dispensed into appropriate wells. 50µl of rabbit anti-Testosterone reagent was dispensed into each well. The plate was mixed thoroughly for 30 seconds. 100µl of Testosterone-HRP Conjugate Reagent was dispensed into each well. The plate was incubated at 37°C for 90 minutes. The microwells were rinsed and flicked 5 times with washing buffer. 100µl of TMB substrate was dispensed into each well, the plate was gently mixed for 10 seconds. The microwells were incubated at room temperature for 20 minutes. The whole reaction was stopped by adding 100µl of Stop Solution to each well. The plate was mixed for 30 seconds. It was ensured that all the blue colour changed to yellow completely. Absorbance was read at 450nm with a microtiter plate reader within 15 minutes.

Testicular Histological Evaluation

Surgical castration was carried out after the study on 2 representatives per group. Testicular biopsy 1cm³ from each animal was taken, and fixed in Bouin's fluid, then dehydrated in graded levels of alcohol, embedded in paraffin wax and sectioned by a microtome at 5-6µm thick. Once cut, the tissue ribbons were carefully transferred and floated on a warm water bath to dewax and then scooped up with a slide placed under the water level. The slides were stained with Hematoxylin-Eosin stain (Suvarna *et al.* 2019). The structures on the stained slides were examined under a light microscope at x10 and x40 magnification.

Descriptive statistics was used for data analysis. Difference between means of control and treatment groups for body weight, measurement of scrotal circumference, semen parameters and serum testosterone concentrations were determined using Two Way Analysis of Variance (ANOVA). The level of significance was set at $p < 0.05$. Values were given as means \pm SD. Field, A. (2018). SPSS program version 16.0 was used.

RESULTS

Clinical Observation

All bucks were examined clinically during the study period for any abnormalities. The testes became swollen and tender in all burdizzo bucks 24 hours after burdizzo procedure. Hydrocele was observed in two bucks each of the one clamp and two clamp burdizzo groups. Also observed were anorexia and recumbency in the burdizzo groups. In the control group, no adverse reaction was recorded.

Weight (KG)

There was a decrease in the weight of the bucks by 24.4% and 29.95% in one clamp and two clamps burdizzo groups respectively from week zero to week four post clamping (Figure 1).

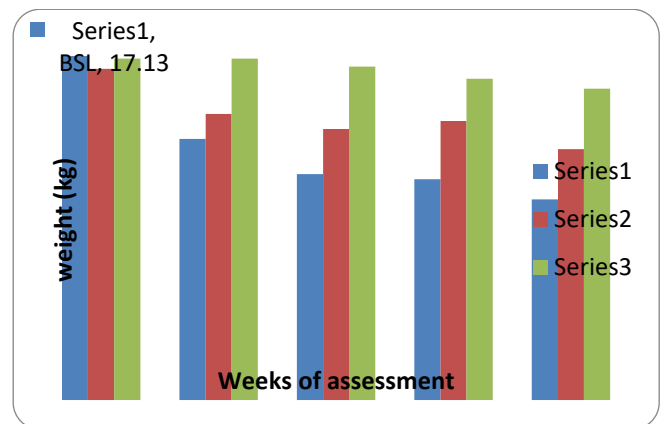


Figure 1: The weight of Red Sokoto bucks, following burdizzo castration.

KEY:
BSL = BASELINE
Series 1 = 1 clamp
Series 2 = 2 clamps
Series 3 = Control

In one clamp burdizzo group, there was a decrease from baseline to week 1, a slight increase at week 2, and a progressive decrease at weeks 3 and 4.

In two clamps burdizzo group, there was a progressive decrease from week 1 to week 3, there was however a slight increase at week 4. In the control group, there was a progressive decrease in weight from weeks 1 to 4.

Scrotal Circumference

Testicular scrotal circumference of the treatment groups showed a weekly decline. There was 25% and 22% decrease in one clamp and two clamps burdizzo groups respectively. In one clamp burdizzo group, there was a progressive decrease from baseline to week 3 and steady at week 4. In two clamps burdizzo group, there was a decrease in scrotal circumference from baseline to week 2, steady at week 3, and then a slight decline at week 4 (Figure 2). In the control group, scrotal circumference was steady.

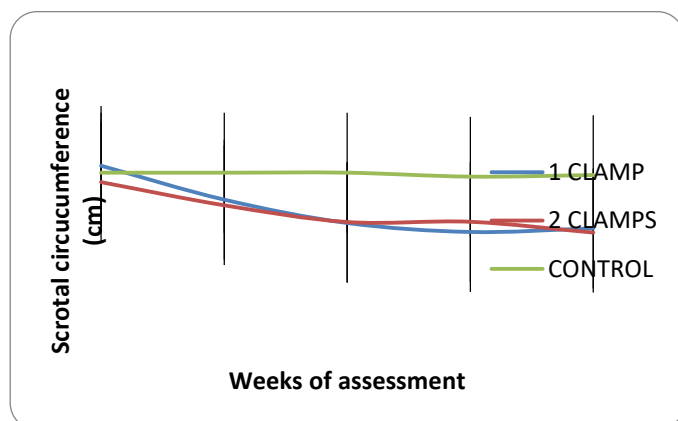


Figure 2: The testicular scrotal circumference of Red Sokoto bucks, following burdizzo castration. KEY BSL = BASELINE

There was no significant difference ($P>0.05$) in the scrotal circumferences of the control group and the treatment groups. Similarly, there was no significant difference ($P>0.05$) in the scrotal circumference between the burdizzo groups.

Semen Characteristics

Semen Volume

In one clamp burdizzo group, there was a progressive decrease in semen volume at week 1 and week 2, a slight increase at week 3, and a decrease at week 4. In two clamps burdizzo group, there was a sharp decrease at week 1, a slight increase at weeks 2 and 3, and a decrease at week 4. In the control group, there was a slight increase at week 1, a decrease at week 2, and a rebound at weeks 3 and 4 (Figure 3).

There was no significant difference in ejaculate volume

between all the groups from week 0 to week 2. At weeks 3 and 4, there was a significant difference in ejaculate volumes between the control group (2.0 ± 1.37 & 2.13 ± 0.71) compared to one clamp (0.75 ± 0.07 & 0.60 ± 0.42) and two clamps (0.43 ± 0.31 & 0.25 ± 0.07) burdizzo groups.

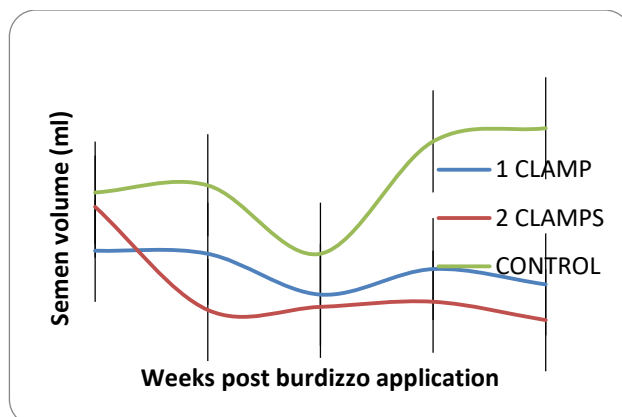


Figure 3: The semen volume of Red Sokoto bucks, following burdizzo castration. KEY BSL = BASELINE

Semen Colour

At week zero, semen colour of all groups were creamy. By weeks 1 and 2 after burdizzo application, semen colour was creamy in the control group and milky in the treatment groups. At week 3, semen was watery in two clamps group, slightly milky in one clamp and creamy in the control group. By week 4, it was watery in the burdizzo groups and creamy in the control group (Table 1).

Table 1: Semen colour of Red Sokoto bucks following burdizzo castration.

TIME	1 CLAMP	2 CLAMP	CONTROL
BASELINE	+++	+++	+++
1 WEEK POST BURDIZZO	++	++	+++
2 WEEKS POST BURDIZZO	++	++	+++
3 WEEKS POST BURDIZZO	++	+	+++
4 WEEKS POST BURDIZZO	+	+	+++

KEYS:
 Semen colour += Watery
 Semen colour ++ = Milky
 Semen colour +++ = Creamy

Progressive Motility

There was 15.1% and 100% decrease in gross motility in the control and burdizzo groups respectively from week zero to week four. In one clamp burdizzo group, there was a progressive decrease from week 0 to week 4.

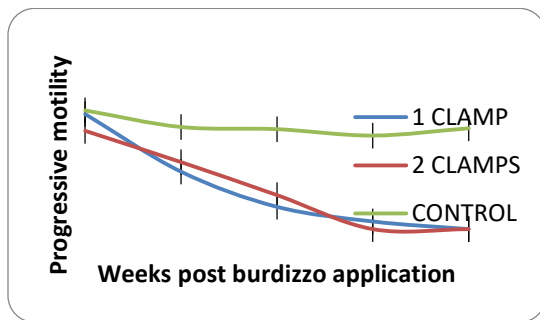


Figure 4: The progressive motility of Red Sokoto bucks, following burdizzo castration.

In two clamps burdizzo group, there was a progressive decrease from weeks 0 to 3, progressive motility was zero at weeks 3 and 4. In the control group, there was a decrease in progressive motility from weeks 1 to 3, however, there was an increase at week 4 (Figure 4). There was no significant difference in sperm motility among all the groups before burdizzo application. One week to four weeks post burdizzo application, progressive motility in one clamp (45.0 ± 29.86 to 0.0 ± 0.0) and two clamps (52.5 ± 27.54 to 0.0 ± 0.0) groups showed a significant decrease compared to the control group (80.0 ± 5.0 to 79.0 ± 6.93).

Spermatozoa Concentration

There was 21% increase in spermatozoa concentration in the control group and 100% decrease in the burdizzo groups from week zero to week four. In one clamp and two clamps burdizzo groups, there was a sharp progressive decrease in spermatozoa concentration from week 0 to week 4. It was zero at weeks 4 and 3 in one clamp and two clamps burdizzo groups respectively. In the control group, there was a slight increase in spermatozoa concentration at week 1, a progressive decrease at weeks 2 and 3, and a rebound at week 4. There was a significant difference ($P < 0.05$) in concentration when comparing the control group with the burdizzo groups (Figure 5). However, there was no significant difference in sperm concentration between the burdizzo groups.

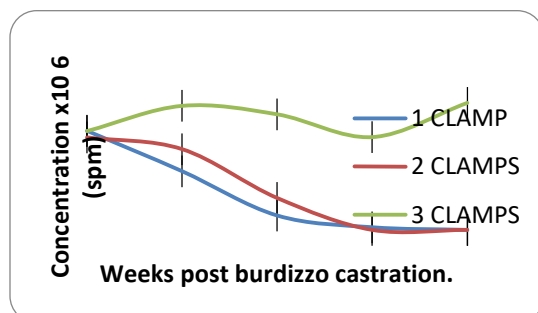


Figure 5: Sperm concentration of Red Sokoto bucks before and after burdizzo castration.

Percentage Sperm Livability

Sperm livability had a high percentage in the control group, however, there was 100% decrease in one clamp and two clamps burdizzo groups respectively from baseline to week four. One clamp and two clamps burdizzo groups showed a progressive decline in percentage sperm livability from baseline to week 4. It became zero at weeks 3 and 4 in two clamps and one clamp burdizzo groups respectively. In the control group, there was a slight decrease at week 1, an increase at week 2, a slight decrease at week 3 and an increase at week 4. There was a significant difference ($P < 0.05$) in sperm livability between the control and burdizzo groups from weeks 2 to 4. However, there was no significant difference ($P > 0.05$) in sperm livability between the burdizzo group. (Figure 6)

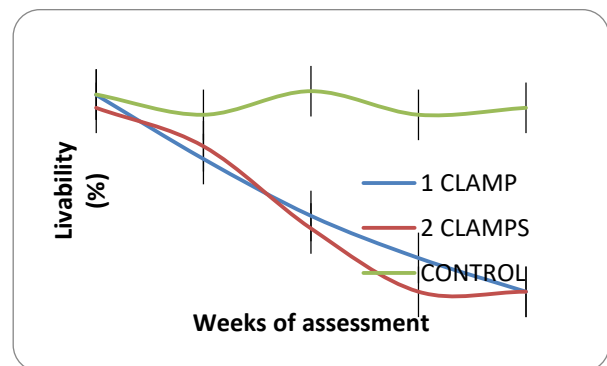


Figure 6: Percentage livability of Red Sokoto bucks, before and after burdizzo castration.

Spermatozoa Morphology

In one clamp burdizzo group, spermatozoa morphological abnormalities showed a progressive increase from baseline to week 4. At baseline, coiled tail and tailless head had the highest percentage. At weeks one to three, tailless head had the highest percentage of abnormalities (46.1%, 57.8% and 86.9%) respectively. At week 4, azoospermia was observed. The highest percentage of abnormalities was at week 4 (100%).

In two clamps burdizzo group, there was a progressive increase in spermatozoa morphological abnormalities from baseline to 3. Tailless head had the highest percentage of abnormalities at baseline (31.5%), week 1 (77.7%) and week 2 (52.5%) respectively. Azoospermia was observed at weeks 3 and 4. The highest percentage of all abnormalities was observed at weeks 3 and 4 (100%). In the control group, there was a decrease in spermatozoa morphological abnormalities at week 1, an increase at weeks 2 and 3 and then a decrease at week 4. Tailless head had the highest percentage of abnormalities from baseline to week 4 with the values 36.4%, 30.6%, 46.5%, 24.2% and 16.8% respectively.

Highest percentage of abnormality was observed at week 2. There was no significant difference in spermatozoa morphology among the three groups from baseline to week 2. From weeks 3 to 4, spermatozoa morphology of the burdizzo groups was significantly different from the control group. (Figure 7).

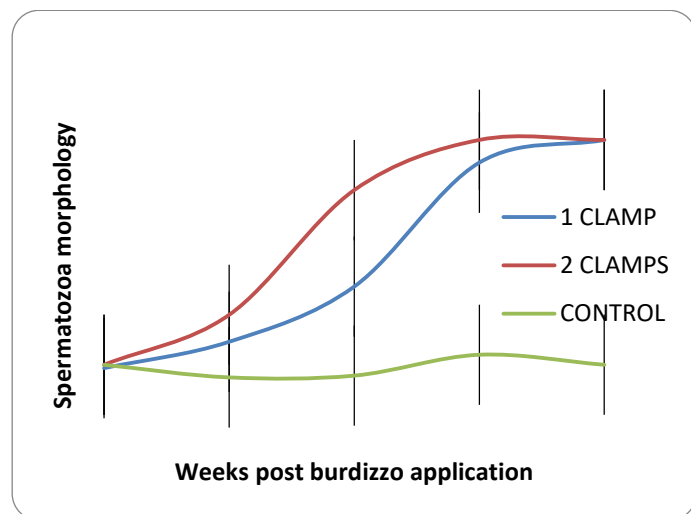


Figure 7: The spermatozoa morphology of Red Sokoto bucks, following burdizzo castration.

Semen pH

Semen pH showed no significant difference among all groups $P > 0.05$. (Table 2)

Table 2: Semen pH of Red Sokoto Bucks, following burdizzo castration.

TIME	1 CLAMP	2 CLAMP	CONTROL
BASELINE	7.34±0.31 ^a	7.13±0.20 ^a	7.15±0.18 ^a
1 WEEK POST BURDIZZO	7.00±0.42 ^a	7.31±0.31 ^a	7.31±0.40 ^a
2 WEEKS POST BURDIZZO	7.15±0.18 ^a	7.34±0.14 ^a	7.09±0.25 ^a
3 WEEKS POST BURDIZZO	7.32±0.65 ^a	7.14±0.48 ^a	7.17±0.38 ^a
4 WEEKS POST BURDIZZO	7.18±0.64 ^a	7.22±0.42 ^a	7.28±0.16 ^a

Values on the same column and row with different superscripts are significant at $P < 0.05$

Serum Testosterone Concentration

In one clamp burdizzo group, there was a sharp decline in serum testosterone concentration from baseline to week 1, a slight increase at week 2 and a progressive decrease at weeks 3 and 4. In two clamps burdizzo group, there was a progressive decrease from baseline to week 4. In the control group, there was a decline in serum testosterone concentration at week 1, a slight rebound at weeks 2 and 3, and then a slight decrease at week 4. There was a significant difference ($P < 0.05$) in serum testosterone concentration at baseline, when comparing one clamp burdizzo group (8.96 ± 6.38) with

two clamps (4.65 ± 2.91) and control (3.26 ± 2.58) groups. However, there was no significant difference ($P > 0.05$) in serum testosterone concentration between all the groups after burdizzo procedure. (Figure 8)

Histology of the Testes and Epididymis

The histopathological changes were the same in the burdizzo groups, irrespective of the number of clamps, but variations were observed in terms of severity, duration and distribution of the lesions. In the control group, testicular section showed normal arrangement of germ cells (spermatogonia) on the basement membrane of the seminiferous tubules. There are distinct peritubular spaces between the tubules which contain leydig cells. In two clamps group, there was severe diffuse degeneration and coagulative necrosis of the germinal epithelial layers and interstitial proliferation of fibrous connective tissues constricting and effacing (atrophy) the seminiferous tubules. There was absence of Leydig cells in the interstitial space. Many of the epididymis were empty and few contained slightly eosinophilic proteinaceous fluid. Epithelial tubules were dilated and compressed and replaced by fibrous connective tissue. Blood vessels were also empty. In one clamp group, epididymis was not as compressed and tubules are not as dilated as that of two clamps group. (Figure 9-14)

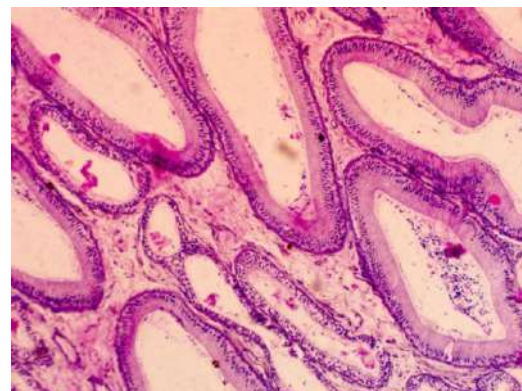


Figure 9: Normal epididymis with sperm cells (H&E X10).

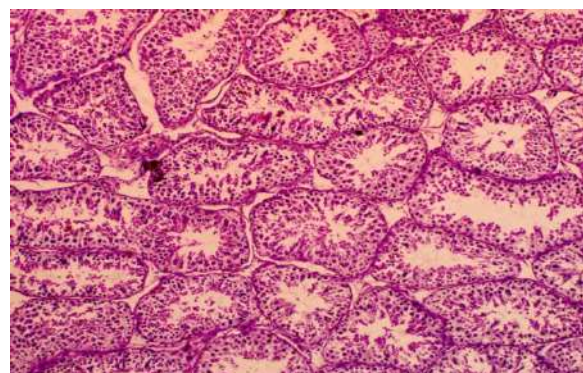


Figure 10: Normal seminiferous tubules (H&E X10).

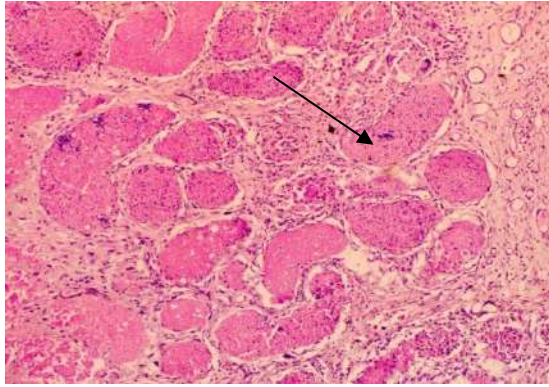


Figure 11: The histology of the testis four weeks after two clamps burdizzo procedure (H&E X10) Key:
 → Fibrous connective tissues

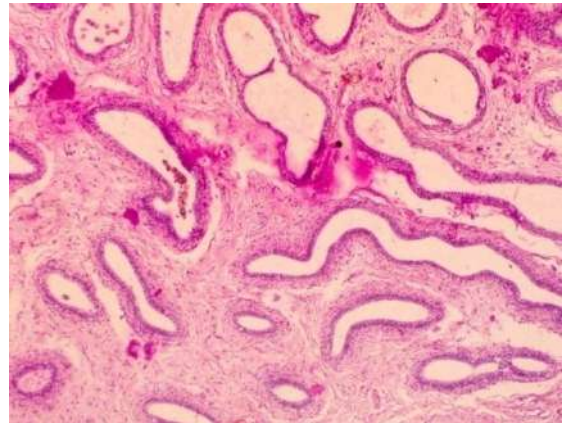


Figure 14: The epididymis of a Red Sokoto buck four weeks after burdizzo procedure (H&E X10).

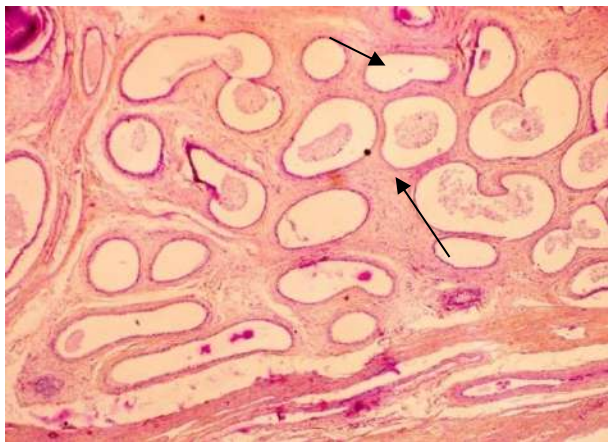


Figure 12: The histology of the epididymis of Red Sokoto buck at four weeks post two clamp burdizzo application. H&E (X10)

Keys:
 → Empty blood vessel
 → Eosinophilicproteinaceous fluid

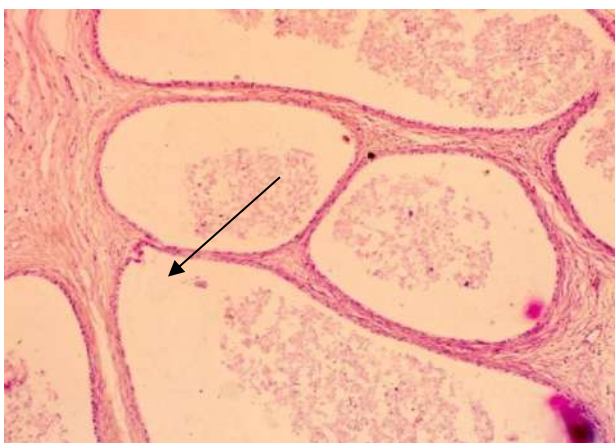

Figure 13: The epididymis of a Red Sokoto buck four weeks after two clamps burdizzo procedure (H&E X40).
 KEY:
 → Dilated epithelial tubule

DISCUSSION

The clinical signs observed in this study, including recumbency, anorexia, and reduced activity, indicate that Burdizzo castration induces significant discomfort in treated animals. These behavioral responses are widely recognized indicators of pain in small ruminants. This finding aligns with recent animal welfare studies, which report that even non-surgical castration techniques such as Burdizzo application result in measurable pain and stress responses (Kongara *et al.*, 2023; Robertson *et al.*, 1994). Furthermore, pain associated behavioral changes such as reduced feeding and altered posture have been consistently reported following castration procedures. The occurrence of hydrocele in both treatment groups may be attributed to disruption of lymphatic drainage and vascular integrity following spermatic cord crushing. Similar post castration complications have been documented in studies evaluating testicular vascular damage and fluid accumulation following castration (Colbourne *et al.*, 1996).

The reduction in body weight observed in the treatment groups compared to control group is likely associated with reduced feed intake resulting from post-procedural pain and stress. Pain-induced anorexia is well documented response in livestock following invasive or stressful procedures.

Recent studies have shown that physiological stress and pain negatively affect feed intake and growth performance in livestock animals (Vinicius *et al.*, 2022). Additionally, stress related hormonal changes can alter metabolic processes, further contributing to reduced weight gain.

Thus, the observed weight loss in this study is consistent with established physiological responses to stress and pain following castration. The reduction in scrotal circumference observed in both treatment groups reflects progressive testicular atrophy following vascular occlusion. This reduction is a direct consequence of degeneration of testicular tissue due to impaired blood supply. Similar findings have been reported in recent

studies where disruption of testicular blood flow led to decreased testicular size and structural degeneration (Nev *et al.*, 2024). Additionally, testicular shrinkage is widely recognized as a reliable indicator of successful castration, particularly in non-surgical methods where external changes reflect internal degeneration.

The progressive decline in semen volume observed in both treatment groups is indicative of reduced secretory activities of accessory sex glands and degeneration of testicular tissue. This finding is consistent with reports that reduced testicular function leads to decreased seminal plasma production and overall semen output. Studies in goats have shown that impairment of reproductive organs significantly affects semen volume and ejaculate characteristics (Oguejiofor *et al.*, 2018). The slight rebound observed in the control group further confirms that the changes seen in treated animals are due to the castration procedure rather than natural variation. The gradual transition from creamy to watery semen observed in the treatment groups reflect a decline in sperm concentration. Creamy semen is typically associated with high semen density, while watery semen indicates low sperm count. This observation aligns with established knowledge that sperm concentration is a major determinant of semen appearance. Similar trends have been reported in reproductive studies where reduced spermatogenesis resulted in diluted semen consistency (Sharma *et al.*, 2026).

The significant decline in sperm motility and livability observed in both treatment groups indicates progressive impairment of semen function. Motility is highly dependent on testicular health and hormonal regulation. The observed decline is consistent with findings that disruption of testicular blood supply leads to reduced sperm viability and motility (Frederik *et al.*, 2019).

Furthermore, degeneration of seminiferous tubules compromises spermatogenesis, leading to the production of non-viable or poorly motile sperm cells.

The marked reduction in sperm concentration, culminating in azoospermia, confirms the effectiveness of Burdizzo castration in suppressing spermatogenesis. The earlier onset of azoospermia in the two-clamp group suggests more complete vascular occlusion and faster degeneration of testicular tissue. This finding agrees with recent studies demonstrating that castration techniques that more effectively disrupt blood supply result in rapid cessation of sperm production (Sharma *et al.*, 2026). The progressive increase in spermatozoa morphological abnormalities observed in the treatment groups following Burdizzo castration indicates a marked disruption of spermatogenesis and sperm maturation processes. In this study, abnormalities increased steadily over time, reaching 100% in both treatment groups prior to the onset of azoospermia, with a more rapid progression observed in the two-clamp group. This increase in abnormal sperm cells can be attributed to the degeneration of the seminiferous epithelium and

impairment of Sertoli cell function, which play a critical role in supporting spermatogenesis and ensuring proper sperm development. Disruption of testicular blood supply following Burdizzo application leads to hypoxia and nutrient deprivation, resulting in defective spermatogenesis and the production of structurally abnormal spermatozoa.

The predominance of defects such as tailless heads and coiled tails observed in this study suggests abnormalities and epididymal maturation. Similar findings have been reported in studies evaluating testicular damage, where vascular compromise resulted in increased sperm morphological defects due to impaired cellular differentiation (Maxim *et al.*, 2021).

Furthermore, oxidative stress induced by ischemic conditions has been identified as a major factor contributing to sperm abnormalities. Hypoxia-related cellular damage disrupts membrane integrity and cytoskeletal organization, leading to malformed sperm cells (Sharma *et al.*, 2026). The earlier onset and higher rate of morphological abnormalities observed in the two-clamp group further support the hypothesis that greater mechanical disruption of the spermatic cord leads to more severe impairment of testicular function. This is consistent with findings that the extent of vascular occlusion directly influences the severity of spermatogenic damage (Maxim *et al.*, 2021). In contrast, the relatively stable and low levels of abnormalities observed in the control group confirm that the changes seen in the treatment animals were a direct consequence of the castration procedure rather than natural variation.

Overall, the progressive increase in sperm morphological abnormalities observed in this study serves as an early indicator of testicular dysfunction and precedes the development of azoospermia, highlighting its importance as a sensitive marker of reproductive impairment following Burdizzo castration.

The significant decline in serum testosterone levels observed in both treatment groups reflects impaired function of Leydig cells following testicular degeneration. Testosterone plays a critical role in maintaining spermatogenesis and libido. Its reduction is therefore directly associated with decreased reproductive capacity. Recent studies have shown that alterations in testicular blood flow and structure significantly affect testosterone production (Nev *et al.*, 2024).

Additionally, experimental studies in goats demonstrate that testosterone levels are closely linked to semen quality and reproductive performance (Heaton & Varrin, 1994). Histological sections of the burdizzo group testes showed severe diffuse degeneration and coagulative necrosis of the germ cell epithelial layers. There was interstitial proliferation of fibrous connective tissues, replacing the Leydig cells and causing atrophy of the seminiferous tubules.

Many of the epididymis were empty. Our observations are similar to that reported by Al-Asadi *et al.*, (2012).

Inevitable ischaemic necrosis or infarction of the testicles is produced either when occlusion of the arterial supply or the venous drainage of the tissues occur (Zachary, J.F. 2022).

Application of two crushes on the same spermatic cord rapidly decreased the blood flow to the testes with a subsequent quick hypoxia response of the testicular cells leading to coagulative necrosis. Lesions on the bucks that received one clamp of burdizzo were similar to those with two clamp, but not as intense. The control group exhibited normal testicular architecture characterized by well-organized seminiferous tubules with intact germinal epithelium and active spermatogenesis. It was however severe enough to cause irreversible damage. This findings agree with Ortega – Pacheco *et al.*, (2006) who worked on one and two clamps burdizzo application in dogs and also with ischemic degeneration of testicular tissue following vascular occlusion induced by Burdizzo castration, as previously reported in small ruminants and other livestock species (Uzaeet *et al.*, 2024). Similar studies have demonstrated that increased mechanical compression of the spermatic cord leads to severe disruption of blood flow, resulting in accelerated degeneration of testicular tissue (Jason *et al.*, 2016).

Furthermore, the observed depletion of germ cells and structural collapse of seminiferous tubules aligns with established mechanisms of testicular atrophy following castration, where hypoxia and nutrient deprivation lead to progressive cellular degeneration (Kongara *et al.*, 2023) Semen pH showed no significant difference $P > 0.05$ in the control and treatment groups. This may be due to the fact that during burdizzo castration, only the testes were affected, the accessory sex gland remained intact, still maintaining the normal pH.

Conclusion

Burdizzo castration caused a significant decrease in weight, semen parameters, scrotal circumference, evidenced by the histopathology of the testes. Azoospermia was achieved as early as the third week in two clamps group while one clamp group had azoospermia in the fourth week. This indicates that the application of one and two clamps of burdizzo on the spermatic cord are effective but two clamps burdizzo application attains a faster result than just one clamp. This demonstrates the effectiveness of castration by burdizzo using one clamp or two clamps method.

Recommendation

Veterinarians should apply two crushes of burdizzo to each spermatic cord to attain a faster result but should wait for three weeks before returning the burdizzo castrated buck to their flock.

Credit Authorship Contribution Statement

Okunowo, O.O wrote the draft manuscript. Ajayi, O.L, Oni O.O. and Bassahwa A.P analyzed the data; all authors reviewed and approved the final manuscript.

Declaration of competing interest

The authors declare that the research was conducted in the absence of any commercial or financial relationships that could be construed as a potential conflict of interest. All claims expressed in this article are solely those of the authors and do not necessarily represent those of their affiliated organizations or those of the publisher, the editors, or the reviewers.

ACKNOWLEDGMENTS

The authors would like to express special thanks to Mr & Mrs Oloruntuga, for their financial support. We are also grateful to the staff of COLVET FUNAAB for their technical assistance.

REFERENCES

- Akhigbe, R.E., Odetayo, A.F., Akhigbe, T.M., Hamed, M.A., Ashonibare, P.J. (2024). Pathophysiology and management of testicular ischemia/reperfusion injury: Lessons from animal models. *Heliyon* 10(9), e27760. <https://doi.org/10.1016/j.heliyon.2024.e27760>.
- Al-Asadi R.N., & Al-KadiKh.K. (2012). Non-surgical castration in bucks: A comparative study between chemical castration and external ligation of the spermatic cord. *Al-Qadisiya Journal of Veterinary Medical Science*. 11(1), 92-102. <https://www.researchgate.net/publication/330530310>.
- Chenoweth P.J., McPherson, F.J. (2016). Bull breeding soundness, semen evaluation and cattle productivity. *Animal Reproduction Science* vol. 169, 32-36. <https://doi.org/10.1016/j.anireprosci.2016.03.001>.
- Colbourne, C.M., Adkins, A.R., Yovich, J.V. (1996). Hydrocele formation after castration in 3 geldings. *Aust Vet J.* 73(4),156-157. <https://doi.org/10.1111/j.1751-0813.1996.tb10011.x>
- Field, A. (2018). *Discovering statistics using IBM SPSS statistics* (5th ed.). Sage Publications. <https://doi.org/10.4135/9781526424532>
- Frederik, M.J., Trine, M.R., Mikkel Fode, Peter, B.O., Jens S., Dana, A.O, Christian, F.S.J. (2019). The Impact of Testicular Torsion on Testicular Function. *World J Mens Health.* 38(3),298-307. <https://doi.org/10.5534/wjmh.190037>
- Heaton, J.P., Varrin, S.J. (1994). Effects of castration and exogenous testosterone supplementation in an animal model of penile erection. *J Urol.* 151(3):797-800. [https://doi.org/10.1016/s0022-5347\(17\)35090-5](https://doi.org/10.1016/s0022-5347(17)35090-5)
- Jason G., Gautam D., Yefim R.S., Noel, L.S., Sardar, A.K. (2026). Testicular compartment syndrome: an overview of pathophysiology, etiology, evaluation, and management. <https://doi.org/10.21037/tau.2016.11.05>
- Kanchan, Matharoo, J.S. (2026). Effects of semen colour on seminal characteristics in cattle bulls. *Indian Journal of Animal Research* 49(1), 146-147. <https://doi.org/5958/0976-0555.2015.00031.X>
- Kongara, K., Singh, P., Venkatachalam, D., & Chambers, J.P. (2023). Pain assessment in goat kids: Focus on disbudding. *Animals*, 13(24), 3814. <https://doi.org/10.3390/ani13243814>
- Maxim Kleshech, Alexander Osadchuk, Ludmila Osadchuk. (2021). Impaired aemen quality, an increase of sperm morphological defects and DNA fragmentation associated with environmental pollution in

- urban population of young men from Western Siberia, Russia. *PLoS One*. <https://doi.org/10.1371/journal.pone.0258900>
- Nev, T.O., Orakpoghenor, O, Terfa, A.J. (2024). Different Castration Methods Induced Variations in Behavioural Responses, Scrotal Circumference and Testicular Histo-architecture in Red Sokoto Bucks. *Sahel J. Vet.Sci.* Vol 21, No. 1, Pp 13-18. <https://doi.org/10.54058/saheljvs.v21i1.438>
- Oguejiofor, Chike, F., Ochiogu, Izuchukwu, S., Okoro, Okechi, L., Ogbu, Vitalis U. (2018). Consequences of unilateral cryptorchidism on semen and sperm characteristics in West African Dwarf Goats. *Asian Pacific Journal of Reproduction.* 7(4),172-177. <https://doi.org/10.4103/2305-0500.237055>
- Ortega - Pacheco A. 2006. Reproduction of dogs in the tropics, with special reference to the population structures, reproductive patterns and pathologies, and a non-surgical castration alternative. *Doctoral dissertation. ISSN: 1652-6880, ISBN: 91-576-7107-9*
- Robertson I.S., Kent, J.E., Molony, V. (1994). Effect of different methods of castration on behavior and plasma cortisol in calves of three ages. *Res Vet Sci.* 56(1),8-17. [https://doi.org/10.1016/0034-5288\(94\)90189-9](https://doi.org/10.1016/0034-5288(94)90189-9)
- Senger, P.L. (2020). *Pathways to pregnancy and parturition* (3rd ed). Current conceptions. <https://doi.org/10.21427/9k6f-5g34>
- Sharma, Dinesh, Parsaila, Niitesh, Navale, Archana, Shinde, Sagar, Patidar, Nishant, Nahar, Prachi, Shelke, Ajay, Solanki, Nilay. (2026). *Asian Pacific Journal of Reproduction.* 15(2),49-56. https://doi.org/10.4103/apjr.apjr_62_25
- Suvarna, S.K., Layton, C., & Bancroft, J.D. (2019). *Bancroft's theory and practice of histological techniques* (8th ed.). Elsevier. <https://doi.org/10.1016/C2015-0-00143-4>
- Uzae,K.Z., Trindade, P.H.E., Rattes, P.Z., Campos, A.L.S., Bernal, L.G., Teixeira, MM.B., Garcia, H.D.M., Pupulim, A.G., Denadai, R., Rossi, E.S., Kastelic, J.P., Ferreira, J.C.P. (2024). Acute post-orchidectomy pain does not reduce alpha rams' interest in feed resources. *Frontiers in Veterinary Science,* 11, 1299550. <https://doi.org/10.3389/fvets.2024.1299550>
- Vinicius, N.G., Reinaldo, F.C., Rodrigo, S.M. (2002). Impacts of stress-induced inflammation on feed intake of beef cattle. *Front Anim Sci.* Volume 3. <https://doi.org/10.3389/fanim.2022.962748>
- Zachary, J.F. (2022). *Pathologic basis of veterinary disease* (7th ed.). Elsevier. <https://doi.org/10.1016/C2017-0-01172-0>.